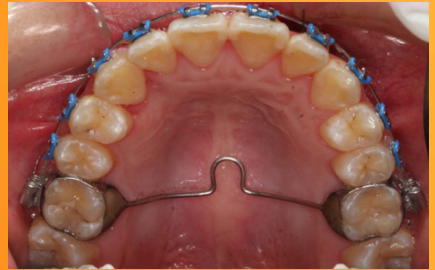
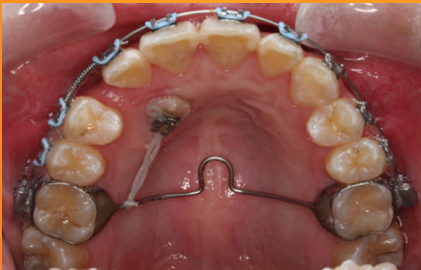
**Oral Health Division
Ministry of Health Malaysia**

MANAGEMENT OF THE PALATALLY ECTOPIC CANINE

(Second Edition)



June 2016

STATEMENT OF INTENT

These clinical practice guidelines (CPG) are meant to be a guide for clinical practice, based on the best available evidence at the time of development. However, adherence to these guidelines may not necessarily lead to the best clinical outcome in individual patient care. Healthcare providers are responsible for the management of their patients based on the clinical presentations and management options available locally.

REVIEW OF THE GUIDELINES

These guidelines were issued in June 2016 and will be reviewed in June 2021 or earlier if new evidence becomes available.

Published by:

Oral Health Technology Section
Oral Health Division
Ministry of Health Malaysia
Level 5, Block E10, Precinct 1
Federal Government Administrative Centre
62590 Putrajaya, Malaysia

Copyright

The copyright owner of this publication is Oral Health Division, Ministry of Health Malaysia (OHD). The contents may be reproduced in any format or medium provided that acknowledgement to the OHD is included and the contents are not changed, sold, used to promote or to endorse any product(s) or service(s) or used inappropriately in misleading context. As for Figure 7 (pg. 7), permission to use shall be granted from George Warman Publications (UK) Ltd.

ISBN: 978-967-0769-56-1

Available on the following websites:

- <http://www.moh.gov.my>
- <http://www.ohd.gov.my>
- <http://www.acadmed.org.my>
- Android and iOS platform: MyMaHTAS

TABLES OF CONTENTS

	Title	Page
	LEVELS OF EVIDENCE AND GRADES OF RECOMMENDATION	i
	GUIDELINE DEVELOPMENT AND OBJECTIVES	iii
	CLINICAL QUESTIONS	iv
	TARGET POPULATION, TARGET GROUP/USER, HEALTHCARE SETTINGS	iv
	MEMBERS OF THE GUIDELINE DEVELOPMENT GROUP	v
	MEMBERS OF THE REVIEW COMMITTEE	vi
	ALGORITHM FOR MANAGEMENT OF THE PALATALLY ECTOPIC CANINE	vii
1.	INTRODUCTION	1
	1.1 Aetiology	1
	1.2 Sequelae of Canine Ectopia	2
2.	DIAGNOSIS AND MANAGEMENT	2
	2.1 History and Examination	2
	2.2 Visual Inspection	3
	2.3 Palpation	3
	2.4 Radiographic Examination	4
3.	TREATMENT	7
	3.1 Interceptive Treatment by Extraction of Deciduous Canine	7
	3.2 Surgical Exposure with or without Orthodontic Traction	10
	3.3 Autotransplantation	12
	3.4 Surgical Removal of PEC	14
	3.5 No Intervention and Observation	14
4.	CONCLUSION	15
5.	IMPLEMENTING THE GUIDELINES	16
	REFERENCES	17
	GLOSSARY	22
	LIST OF ABBREVIATIONS	26
	ACKNOWLEDGEMENTS	27
	DISCLOSURE STATEMENT	27
	SOURCE OF FUNDING	27

LEVELS OF EVIDENCE

LEVEL	STUDY DESIGN
I	Evidence obtained from at least one properly designed randomised controlled trial.
II-1	Evidence obtained from well-designed controlled trials without randomization.
II-2	Evidence obtained from well-designed cohort or case-control analytic studies, preferably from more than one centre or research group.
II-3	Evidence obtained from multiple time series studies, with or without intervention. Dramatic results in uncontrolled experiments (such as the results of the introduction of penicillin treatment in the 1940s) could also be regarded as this type of evidence.
III	Opinions or respected authorities, based on clinical experience; descriptive studies and case reports; or reports of expert committees.

Source: Adapted from Harris RP, Helfand M, Woolf SH, Lohr KN, Mulrow CD, Teutsch SM, Atkins D. Current Methods of the U.S. Preventive Services Task Force: A Review of the Process. Am J Prev Med. 2001;20(suppl 3):21-35.

GRADES OF RECOMMENDATION

GRADE	STUDY DESIGN
A	At least one meta-analysis, systematic review or Randomised Controlled Trial (RCT) or evidence rated as good or directly applicable to the target population.
B	Evidence from well conducted clinical trials, directly applicable to the target population and demonstrating overall consistency of results; or evidence extrapolated from meta-analysis, systematic reviews or RCT.
C	Evidence from expert committee reports, or opinions and/or clinical experiences of respected authorities; indicates absence of directly applicable clinical studies of good quality.

Source: Modified from the Scottish Intercollegiate Guidelines Network (SIGN 50). A guideline developer's handbook. Elliott House, 8 -10 Hillside Crescent Edinburgh EH7 5EA. Revised November 2011. ISBN 978 1 905813 25 4.

Note: The grades of recommendation relates to the strength of the evidence on which the recommendation is based. It does not reflect the clinical importance of the recommendation.

GUIDELINES DEVELOPMENT AND OBJECTIVES

GUIDELINES DEVELOPMENT

The members of the Development Group for these Clinical Practice Guidelines (CPG) on Management of the Palatally Ectopic Canine (PEC) consisted of Orthodontists, a Paediatric Dental Specialist, Dental Public Health Specialists, a general dental practitioner and a dental nurse. The Review Committee was actively involved in the development process of these guidelines.

The previous edition of the CPG on the Management of the Palatally Ectopic Canine (2004) was used as the basis for the development of these guidelines. Several improvements have been introduced in this edition. In addition to the general text and photographic updates, new and updated information have been included. In addition, clinical audit indicators have also been identified for the purpose of monitoring referrals.

Evidences were updated from publications until June 2016. Literature search was carried out using the following electronic databases: PUBMED/MEDLINE; Cochrane Database of Systemic Reviews; ISI Web of Knowledge; Health Technology Assessment and full text journal articles via OVID search engine. In addition, the reference lists of all relevant articles retrieved were searched to identify further studies. The following free text terms or MeSH terms were used either singly or in combination to retrieve the articles: “Palatally ectopic canine”, “Impacted maxillary canine”, “Deciduous dentition”, “Permanent dentition”, “Prevalence”, “Epidemiology”, “Aetiology”, “Sequelae of canine ectopia”, “Signs and symptoms”, “Palatal”, “Buccal”, “Periapical”, “Investigations”, “Cone-Beam Computed Tomography”, “Treatment modalities”, “Autotransplantation”, “Interceptive Orthodontics”, “Interceptive treatment”, “Orthodontic Treatment”, “Surgical removal”, “Surgical exposure”, “No intervention”, “Observation” “Complications”, “Pathology”, “Root resorption”, “Ankylosis”, “Dilaceration”, “Cystic”, “Prosthesis” and “Osseointegrate”. Only literatures written in English were retrieved.

There were nine clinical questions which were assigned to members of the development group. The group members met a total of eight times throughout the development of this CPG. All literatures retrieved were appraised by at least two members and presented in the form of evidence tables and discussed during group meetings. All statements and

recommendations formulated were agreed upon by both the development group and review committee. These CPGs are based largely on the findings of scientific evidence and adapted according to local practices. However, where there was lack of evidence, recommendations were based on consensus of group members. Although, ideally patients' views and preferences need to be considered in the development of CPGs, in this instance, it was not feasible. Nevertheless, patient information leaflets would be developed to facilitate the dissemination of important information to the public.

The levels of evidence of the literature were graded using the modified version from the United States Preventive Services Task Force (USPSTF), while the grading of recommendations was based on the modified version of the Scottish Intercollegiate Guidelines Network (SIGN).

The draft guidelines were reviewed by a team of external reviewers and were also posted on the Ministry of Health, Malaysia and the Academy of Medicine, Malaysia websites for comments and feedbacks. These guidelines were presented to the Technical Advisory Committee for CPGs, and finally to the Health Technology Assessment and Clinical Practice Guidelines Council MOH Malaysia for approval.

OBJECTIVE

To provide evidence-based guidelines in the management of the palatally ectopic canine.

SPECIFIC OBJECTIVES

- i. To disseminate and reinforce knowledge on the management of the palatally ectopic canine among healthcare professionals.
- ii. To enable timely recognition and referral of the palatally ectopic canine by healthcare professionals.
- iii. To provide appropriate management of the palatally ectopic canine by healthcare professionals.

CLINICAL QUESTIONS

The clinical questions addressed by these guidelines are:

1. What is the definition of palatally ectopic canine?
2. What is the prevalence of palatally ectopic canine?
3. What are the aetiological factors of palatally ectopic canine?
4. What are the complications associated with a palatally ectopic canine?
5. What are the clinical signs of palatally ectopic canine?
6. What are the routine investigations required to diagnose palatally ectopic canine?
7. What further investigations may be recommended to diagnose palatally ectopic canine?
8. What are the advantages and limitations of each diagnostic method?
9. What are the various treatment modalities available in managing a palatally ectopic canine?

TARGET POPULATION

These guidelines are applicable to patients diagnosed with palatally ectopic canine.

TARGET GROUP/USER

This guideline is meant for all oral healthcare providers who provide clinical management of the palatally ectopic canine.

HEALTHCARE SETTINGS

Primary and Specialist Oral Health care settings.

MEMBERS OF THE GUIDELINES DEVELOPMENT GROUP

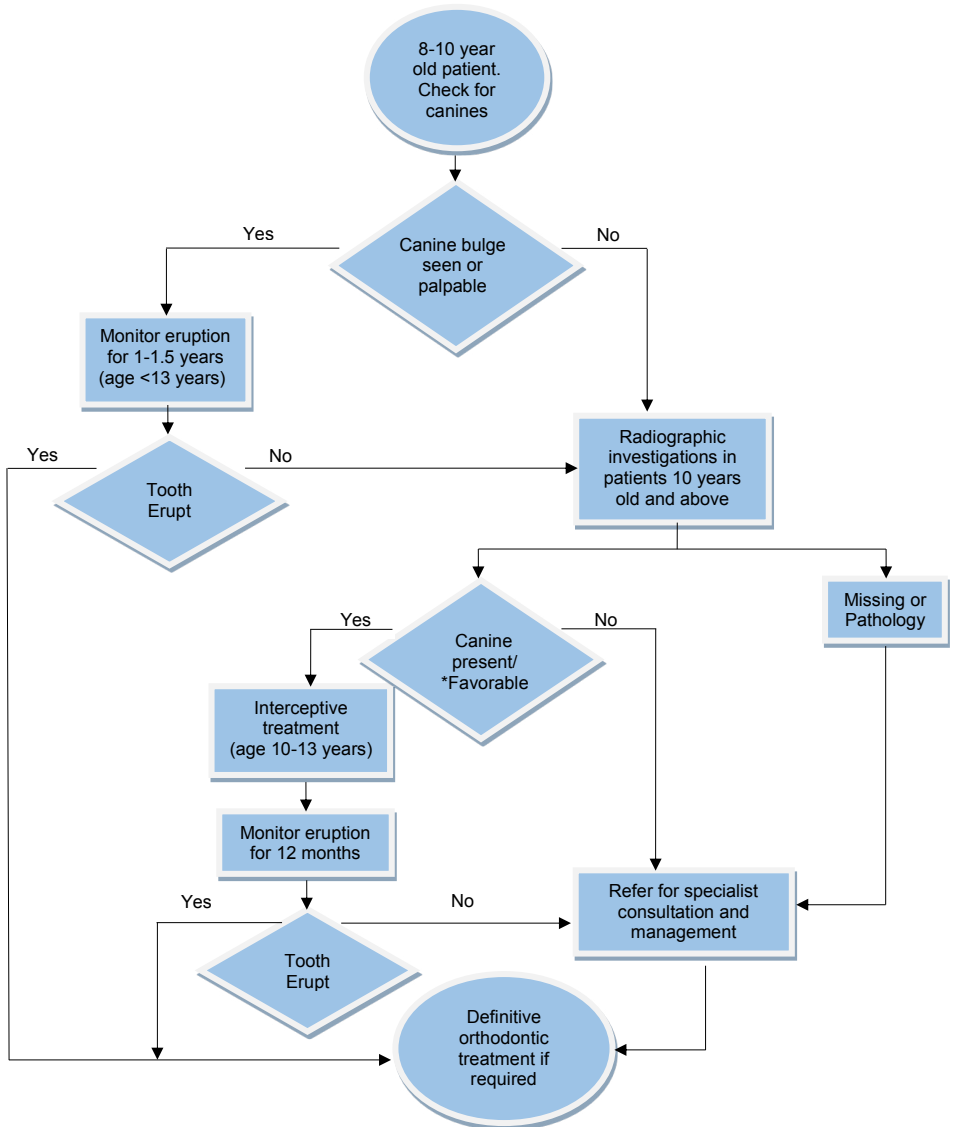
Chairperson	Secretary
Dr Norlian bt. Hj Daud Consultant Orthodontist Unit Ortodontik Klinik Pergigian Bangsar Jalan Bangsar 59200 Kuala Lumpur	Dr Malathi Deva Tata Orthodontist Unit Ortodontik Klinik Pergigian Besar Seremban Jalan Zaaba 70100 Seremban, Negeri Sembilan
Members	
Dr Siti Ena bt. Eden Consultant Orthodontist Unit Ortodontik Klinik Pergigian Besar Seremban Jalan Zaaba 70100 Seremban, Negeri Sembilan	Dr Yatimah bt. Othman Orthodontist Unit Ortodontik Klinik Pergigian Klang Jalan Tengku Kelana 41000 Klang, Selangor
Dr Sarimah bt. Mohd Mokhtar Pediatric Dental Specialist Jabatan Pergigian Pediatrik Hospital Tuanku Ja'afar 70300 Seremban Negeri Sembilan	Dr Ainuddin Yusfar b. Yusof Lecturer and Orthodontist Dental Faculty, Universiti Sains Islam Malaysia Level 15-17, Tower B, Psm MPAJ Jalan Pandan Utama, Pandan Indah 55100 Kuala Lumpur
Dr Zainab bt. Shamdol Dental Public Health Specialist Bahagian Kesihatan Pergigian KKM Aras 5, Blok E10, Kompleks E, Presint 1 Pusat Pentadbiran Kerajaan Persekutuan 62590 Putrajaya	Dr Then Poh Kiu Orthodontist Unit Ortodontik Klinik Pergigian Petra Jaya Off Jalan Siol Kanan, Petra Jaya 93050, Kuching, Sarawak
Dr Puvanendran a/l Balasingham Orthodontist Unit Ortodontik Klinik Pergigian Port Dickson 71000 Port Dickson Negeri Sembilan	Dr Prethiba a/p Yugaraj Orthodontist Unit Orthodontik Klinik Pergigian Dato' Keramat Off Jalan Enggang 54200 Kuala Lumpur
Dr Salleh b. Zakaria Dental Public Health Specialist Bahagian Kesihatan Pergigian KKM Aras 5, Blok E10, Kompleks E, Presint 1 Pusat Pentadbiran Kerajaan Persekutuan 62590 Putrajaya	Dr Asmak bt. Shaari Orthodontist Unit Ortodontik Klinik Pergigian Buntong Persiaran Desa Rishah 2, Taman Desa Rishah 30100 Ipoh, Perak
Dr Sharihan bt. Khashim Orthodontist Klinik Pakar Ortodontik Alor Setar Jalan Tunku Abdul Halim 05100 Alor Setar Kedah	Dr Juhaida bt. Salleh Orthodontist Unit Ortodontik Klinik Pergigian Senawang 70450 Seremban Negeri Sembilan
Dr Mohd Zambri b. Mohamed Makhbul Orthodontist Unit Ortodontik Klinik Pergigian Cahaya Suria Tkt 3, Bangunan Cahaya Suria Jalan Tun Perak 50050 Kuala Lumpur	Dr Amalina bt. Adanan Dental Officer Klinik Pergigian Setapak No. 26-1 & 28-1, Jalan 9/23A, Jalan Usahawan Off Jalan Genting Klang Setapak 53200 Kuala Lumpur
Matron Lim Lean Yeng Dental Therapist Majlis Pergigian Malaysia E301, Aras 3, Blok 3440 Enterprise Building 1, Jalan Teknokrat 3 63000 Cyberjaya, Selangor	

MEMBERS OF THE REVIEW COMMITTEE

These guidelines were reviewed by a panel of independent local and international reviewers. They were asked to comment primarily on the comprehensiveness and accuracy of interpretation of the evidence supporting the recommendations in the guidelines. The following were the reviewers:

INTERNAL REVIEWERS	
<p>Dr Syed Nabil b. Syed Omar Oral & Maxillofacial Surgeon Dept. of Oral and Maxillofacial Surgery Faculty of Dentistry, Universiti Kebangsaan Malaysia Jalan Raja Muda Abdul Aziz 50300 Kuala Lumpur</p>	<p>Associate Prof. Dr Zamri b. Radzi Lecturer and Orthodontist Dept. of Paediatric Dentistry & Orthodontics Faculty of Dentistry, University of Malaya 50603 Kuala Lumpur</p>
<p>Dr Mimi Syazleen bt. Abdul Rahman Paediatric Dental Specialist Jabatan Pergigian Pediatrik Hospital Sungai Buloh 47000 Sungai Buloh Selangor</p>	<p>Dr Sh Maznah bt. Wan Mohammed Periodontist Unit Periodontik Klinik Pergigian Cahaya Suria Tkt 3, Bangunan Cahaya Suria, Jalan Tun Perak 50050 Kuala Lumpur</p>
<p>Dr Fatimah bt. Abdullah Orthodontist Unit Ortodontik Klinik Pergigian Bandar Mentakab Jalan Karak 28400 Mentakab Pahang</p>	<p>Matron Too Bee Kiew Dental Therapist Bahagian Kesihatan Pergigian Jabatan Kesihatan Negeri Negeri Sembilan Jalan Rasah 70300 Seremban Negeri Sembilan</p>
EXTERNAL REVIEWERS	
<p>Professor Balvinder Singh Khambay Clinical Chair Professor of Orthodontics Faculty of Medicine and Health School of Dentistry Clarendon Way Leeds LS2 9LU United Kingdom</p>	<p>Professor Fraser McDonald Head of Orthodontic Department Orthodontic Department Guy's Hospital King's College London Dental Institute Floor 22, Guy's Tower, London SE1 9RT United Kingdom</p>
<p>Dr Hashmat Popat Specialist Orthodontist/Clinical Tutor Faculty of Medicine, Dentistry and Health Sciences Melbourne Dental Clinic University of Melbourne 723 Swanston St Carlton VIC 3010 Australia</p>	

ALGORITHM FOR MANAGEMENT OF THE ECTOPIC CANINE



Note: *Refer to section 3.2. If in doubt, please consult an orthodontist

1. INTRODUCTION

The maxillary canine plays a vital role in the functional aspect of the occlusion. It has a long root and good bony support and is often referred to as the cornerstone of the maxillary arch. Missing or impacted canine will affect the function and aesthetic appearance of the smile.

An impacted tooth can be defined as the failure of a tooth to erupt within the specified time. An impacted canine is a canine that is prevented from erupting into its normal functional position by bone, tooth or fibrous tissue. Palatally ectopic canine (PEC) is defined as the developmental dislocation of the upper canine to a palatal site often resulting in tooth impaction requiring surgical and orthodontic treatments.^{1, level III}

The erupting maxillary canine should be palpable in the buccal sulcus from age of 10 to 11 years.^{2, level II-3} Eruption of maxillary canines after 12.3 years of age in girls and 13.1 years of age in boys may be considered as late.^{3, level III}

Maxillary canine is the second most commonly impacted tooth after the third molar. The prevalence of impaction of maxillary canines ranges from 0.8% to 5.2%.^{4-5,7-8 level III; 6, level II-3} The crowns of ectopic maxillary canines are more often palatally (61%), while 34% are placed in the line of the arch and 4.5% are displaced buccally.^{9, level III} Ectopic maxillary canines are twice as common in girls. In about 8% to 10% of cases, canine impactions occur bilaterally.^{10, level III} Currently, there is no published data available on the prevalence of impacted canines in the Malaysian population.

This CPG is focused on PEC based on the higher prevalence of its occurrence, which requires complex and multidisciplinary management compared to buccally ectopic canine.

1.1 Aetiology

Maxillary canine has the longest path of eruption into the occlusion and the longest period of development. The aetiology of palatally ectopic maxillary canine remains unclear. However, the following are some of the contributing factors. These contributing factors may be either local or general.^{11, level III}

a) General factors

- Systemic diseases such as endocrine deficiencies
- Febrile disease
- Irradiation (a possible contributing factor)

b) Local factors

- Discrepancies between tooth size and arch length
- Retained deciduous canine / failure of the primary canine root to resorb
- Early loss of the deciduous canine
- Missing or peg shaped lateral incisors
- Abnormal position of the tooth bud
- The presence of an alveolar cleft
- Ankylosis of the permanent canine
- Cystic or neoplastic formation
- Dilaceration of the root
- Iatrogenic origin
- Idiopathic condition

Some evidence of familial/genetic occurrence of the PEC has also been found.^{12-13, level III}

1.2 Sequelae of Canine Ectopia

The possible complications associated with a PEC include root resorption of adjacent teeth, dentigerous cyst formation, infection and referred pain.^{6, level II-3; 10,14-17 level III} It has been estimated that 0.6% to 0.8% of children aged 10 to 13 years have permanent incisors with root resorption caused by ectopic canines.^{6, level II-3} 80% of teeth with root resorption are lateral incisors.^{10, level III} Computed Tomography (CT) scanning has detected up to 48% of incisors adjacent to ectopic canines with root resorption.^{15, level III} Cone-Beam Computed Tomography (CBCT) scanning has shown that 66.7% of permanent lateral incisors adjacent to ectopic canines have root resorption and 11.1% of central incisors.^{18, level III}

Key Message 1

PEC may cause root resorption of adjacent teeth, dentigerous cyst formation, infection and referred pain.

2. DIAGNOSIS AND MANAGEMENT

2.1 History and Examination

Palatally ectopic canine should be suspected if the canine is not palpable in the buccal sulcus by the age of 10 to 11 years or if any asymmetrical eruption pattern of canine is noted.^{2, level II-3} Early diagnosis and treatment of the PEC is essential for a successful outcome.^{19, level II-1}

Patients with an ectopic maxillary canine must undergo a comprehensive assessment of the malocclusion including accurate localization of the ectopic canine which is performed by visual inspection, palpation and radiographic assessment.

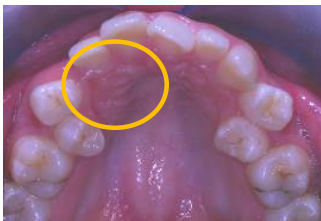Inspection and palpation in the canine region is recommended annually from age 8 years onwards.^{19, level II-1} Clinicians should suspect ectopia^{20, level III} if:

- the canine is not palpable in the buccal sulcus by the age of 10-11 years
- palpation indicates an asymmetrical eruption pattern
- the position of adjacent teeth implies a malposition of the permanent canine

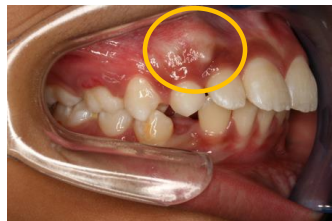2.2 Visual Inspection

The absence and abnormal position of both the canine bulge and lateral incisor can give an indication of canine ectopia (**Figure 1**).

Figure 1: Canine bulge



Canine bulge: Palpable on the palate



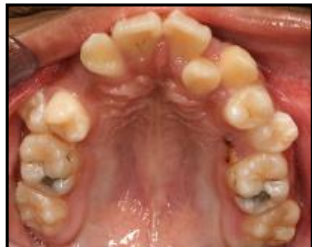Canine bulge: Palpable on the buccal

2.3 Palpation

Palpation of the buccal and palatal mucosa is recommended to assess the position of the erupting maxillary canines. The absence of the canine bulge

or presence of asymmetrical eruption (**Figure 2**) after the age of 10 years may indicate that the canine is ectopic. ^{21, level III}

Figure 2: Asymmetrical eruption



The upper right canine has still not erupted even though the upper left canine has completed eruption more than 6 months ago.

Key Message 2

- Canine ectopia may be suspected by the absence of the canine bulge or presence of asymmetrical eruption after the age of 10 years.
- Position of PEC can be assessed via palpation of the buccal and palatal mucosa.

Recommendation 1

Inspection and palpation in the canine region is recommended annually from age 8 years onwards. (Grade C)

2.4 Radiographic Examination

Radiographs are indicated to confirm and localise the ectopic canine and condition of the adjacent teeth. ^{2, level II-3} Radiographic examination should be prescribed in patient aged 10 years and above as earlier radiographic assessment provides little benefit.

2.4.1 Parallax technique

Parallax technique is the most routinely used radiographic assessment to help localise the ectopic canine. This technique involves taking two radiographs and using the principle of vertical or horizontal parallax ^{22-23, level II-3} (**Figure 3,4 & 5**). Horizontal parallax is superior to vertical parallax in terms of localising the PEC. ^{24, level III}

a) Horizontal Parallax

- Anterior Occlusal and Periapical
or
- Two Periapicals
or
- Two Anterior Occlusals

b) Vertical Parallax

- Anterior Occlusal + Dental Panoramic Tomogram (DPT)
or
- Periapical + DPT

Figure 3: Vertical parallax technique using DPT & anterior occlusal view

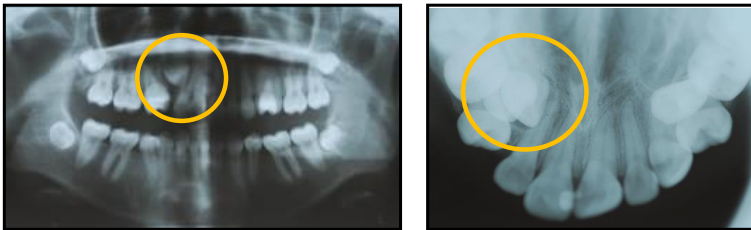
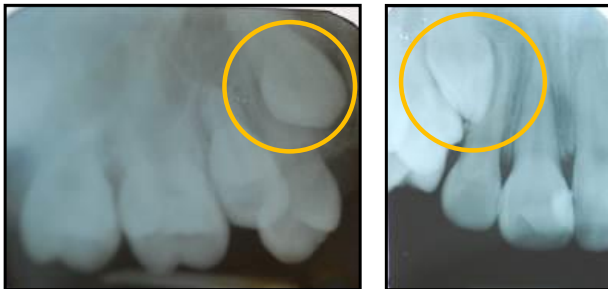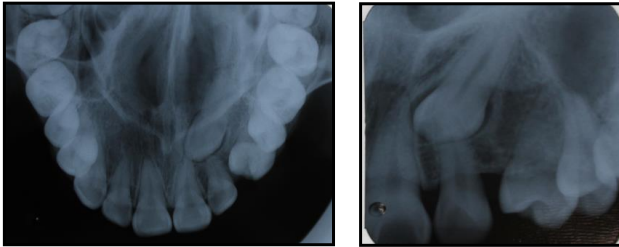


Figure 4: Horizontal parallax technique using two periapical views



The reference object for the parallax technique is normally the root of the adjacent tooth. The image of the tooth that is farther away, from the X-ray tube moves in the same direction, whereas that the tooth closer to the X-ray tube moves in the opposite direction to the tube (SLOB Rule- Same Lingual Opposite Buccal).^{25, level III}

Figure 5: Horizontal parallax technique using an Upper Anterior Occlusal and a periapical view

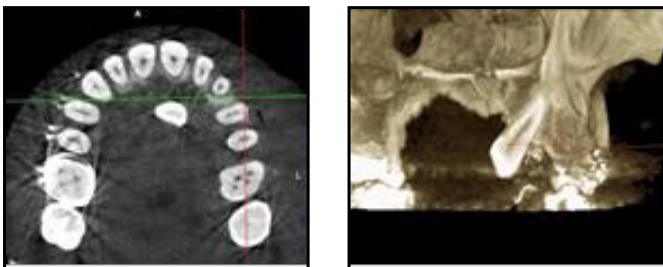


2.4.2 Cone-Beam Computed Tomography

More recently, the use of Cone-Beam Computed Tomography (CBCT) (**Figure 6**) has been described to aid in diagnosis and management of palatally ectopic canine.^{18, level III} CBCT is more accurate in localising the position of the canine in three dimensions and for diagnosing lesions such as root resorption of the adjacent teeth.^{26, level III} Linear and angular measurement on CBCT images are accurate and precise and can be used to assess a precise position of PEC.^{27, level II-2} However, increased radiation exposure and high costs restrict its routine use.^{28, level III} CBCT should be prescribed to overcome shortcomings of conventional radiographs when deemed necessary.

The use of CBCT will allow accurate three-dimensional localisation of the PEC as well as any root resorption of adjacent teeth. This may have effect on the treatment planning process. The decision to request a small volume CBCT scan should be made by an orthodontic specialist following full clinical assessments and appropriate radiological support for reporting.^{29-30, level III}

Figure 6: Cone-Beam Computed Tomography



Recommendation 2

- Radiographic investigation is indicated for patient above 10 years old with clinically missing maxillary canine. (Grade A)
- Parallax radiographic technique should be used to determine the position of the ectopic canine. (Grade C)
- CBCT may be prescribed to overcome shortcomings of conventional radiographs when deemed necessary. (Grade C)

3. TREATMENT

There are various treatment modalities for the PEC. Patient and parent should be counseled on the various treatment options available.

3.1 Interceptive Treatment by Extraction of Deciduous Canine

Timely extraction of deciduous canine in patients aged 10 to 13 years with PEC has been found to normalise the eruptive path of canines within 12 months in 78% of cases^{19, level II-1} and in 62% of cases.^{31, level II-1}

Recent studies also found similar results. Naoumova *et al.*^{32, level I} found 69% in those aged 10 to 13 years had spontaneous eruption of the PEC, while Bazargani *et al.*^{33, level I} found 67% of PEC normalised. It was noted that the effect was significantly more pronounced in the younger patients (10 to 11 years) compared to older patients (12 to 14 years).

The efficacy of this procedure is supported by Naoumova *et al.*^{34, level I} This randomised controlled trial (RCT) found that the greatest predictor on eruption of the PEC was the timely removal of the deciduous canine. This interceptive procedure may reduce treatment complexity, duration, cost and potential complications involved with management of PEC.

3.1.1 Indications

Ericson & Kuroi,^{19, level II-1} listed the following indications:

- a) Patients aged between 10 to 13 years.
- b) Uncrowded arch.
- c) Ectopic canine root still developing.
- d) Horizontal overlap of the ectopic canine crown is not beyond the midline of the nearest lateral incisor root.

Power & Short,^{31, level II-1} reaffirmed the findings regarding the success rate being affected when the horizontal overlap exceed beyond the midline of incisor width. A 91% success rate was reported if the crown of the canine is distal to midline of the lateral incisor and 64% success rate when the crown is located mesial to midline of the lateral incisor.^{19, level II-1} Therefore, early detection is important to ensure greater success rate.

3.1.2 Review

This should be done at 6 monthly intervals with follow-up radiographs until the permanent canines erupt. If there is no improvement after 12 months, other treatment options have to be considered.^{19, level II-1}

3.1.3 Special considerations

- a) In potentially crowded arches, space maintenance or space re-gaining may be required. This can be achieved by appliances or extraction. However, any decision to extract permanent teeth to allow the PEC to erupt must only be undertaken after specialist consultation. Maintenance of the perimeter of the upper arch is an important step during the observation period, and the palatal arch is recommended as a space-holding device.^{33, level I}
- b) Bilateral extractions of deciduous canines may be required to prevent midline shift.






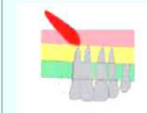






3.1.4 Prognosis

Extraction of the deciduous maxillary canine does not guarantee correction of the problem and therefore the prognosis should be explained to patient and parent/s (**Figure 7**). A residual space may be present following extraction of the deciduous canine if the PEC fails to erupt. They should also be informed of the various options available in the event of an unsuccessful outcome.

Prognosis is less favourable if:

- a) arches are crowded which will most likely indicate complex appliance therapy.^{31, level II-1}
- b) root of the ectopic canine is fully formed.^{35-36, level III}
- c) horizontal overlap of the PEC exceeds beyond the midline of the lateral incisor.^{31, level II-1}

Figure 7: Assessment of treatment prognosis for interceptive treatment of PEC

Category	Good Prognosis	Average	Poor
Overlap of incisor	No horizontal overlap 	Up to half root width 	Complete overlap 
Vertical height	CEJ – halfway up root 	>half <full root length 	>full root length 
Angulation	0–15° 	16–30° 	>30° 
Position of apex	Above canine position 	Above 1st premolar 	Above 2nd premolar 

Reproduced from Dental Update (ISSN 0305-5000), by permission of George Warman Publications (UK) Ltd

Even though the benefits of extraction of deciduous canine were questioned by the Cochrane collaboration,^{37-38, level I} it is still a worthwhile interceptive option if done based on sound clinical and radiographic selection criteria to optimise the potential benefits to the patient. It is cost effective when compared with that of complex orthodontic treatment and surgical intervention required in management of PEC.^{19, level II-1}

Key Message 3

Treatment options and possible outcomes must be discussed with parents and patients.

Recommendation 3

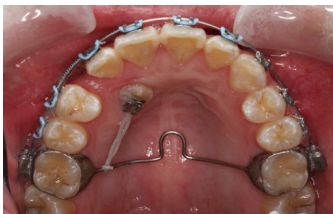- Extraction of deciduous canine as an interceptive management of PEC should be based on sound clinical and radiographic selection criteria. (Grade C)
- Suitable age for extraction of deciduous canine is between 10 to 13 years old in the absence of crowding. (Grade A)

3.2 Surgical Exposure with or without Orthodontic Traction

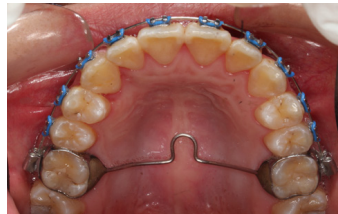The purpose of surgical exposure is to facilitate the eruption of the PEC into the arch. There are three methods for exposure and alignment of the canine,^{39, level III}

- Open surgical exposure and spontaneous eruption
- Open surgical exposure and bonding of attachment for traction
(Figure 8)
- Close surgical exposure and bonding of attachment for traction

Figure 8: Open surgical exposure and bonding of attachment for traction



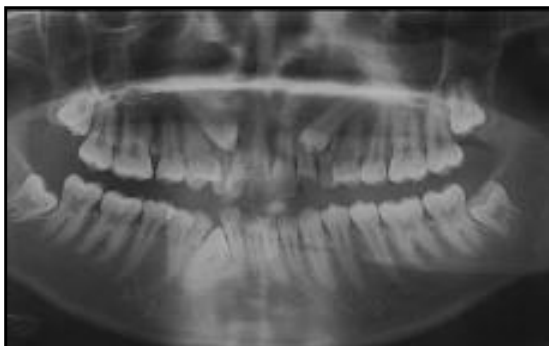
Traction of PEC after open surgical exposure and bonding



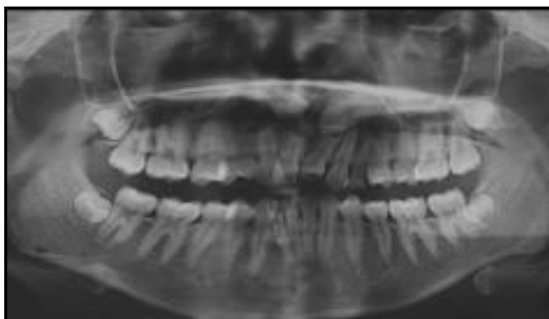
Successful alignment of PEC into the arch

Indications:

- Patient must be willing to wear fixed appliances.
- Since the treatment time is normally prolonged, the general oral health, the cooperation and motivation of the patient should be good.
- When interceptive treatment by extraction of deciduous canine is not feasible and/or not favourable.
- Unsuccessful outcome of interceptive treatment.
- When severe root resorption of the adjacent teeth necessitates extraction of these teeth and alignment of the PEC into the arch.
- When the position of PEC is favourable **(Figure 9)**.

Figure 9: Favourable and unfavourable position of PEC for alignment

Favorable position



Unfavorable position

The success of orthodontic treatment depends on the degree of malposition of the ectopic canine. The rate of success is inversely proportional to the degree of malposition. The degree of malposition of the impacted canine should not be so great that orthodontic alignment is impractical for example close proximity to the midline, above the apices of the adjacent teeth and horizontal angulation.^{20, level III} Fleming *et al.*^{40, level II-2} found that, accurate prediction of the treatment duration for orthodontic alignment of palatally impacted maxillary canine is difficult. The mesiodistal position of the canine may be a useful predictor of treatment duration.

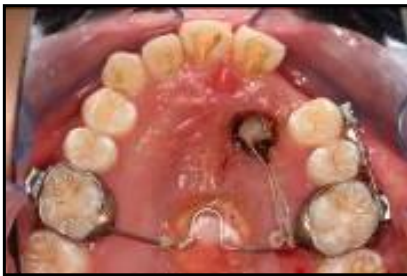The optimal time for surgical exposure and orthodontic treatment is during adolescence.^{41, level III} The success rate of the treatment procedure is quite high. The prognosis for successful orthodontic resolution of an impacted canine in an adult (69.5%) is lower than that in a younger patient(100%) and the prognosis worsens with age.^{42, level II-2}

Inaccurate three dimensional diagnosis of location and orientation of impacted teeth and failure to appreciate anchorage demands were the major reasons for failure in the treatment of impacted canines.^{43, level II-3} Therefore the specialist orthodontist should consider taking a small volume CBCT.^{29-30, level III}

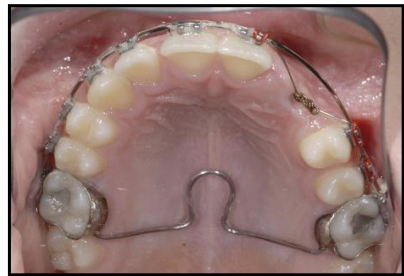There are some clinicians who prefer open exposure and others who prefer closed exposure of the PEC (**Figure 10**). There is no evidence to support one surgical technique over the other in terms of dental health, aesthetics, economics and patients factors.^{44, level III; 45, level I} The choice of technique is best left to the personal choice of the orthodontist and surgeon.

A combination of surgical exposure followed by corticotomy has been shown to produce a faster movement of the palatally ectopic canine tooth into the arch and thus can reduce treatment time.^{46, level III}

Figure 10: Open and closed exposure



Open exposure



Closed exposure

3.3 Autotransplantation

Autotransplantation (**Figure 11**) may be considered when orthodontic alignment of PEC is not possible. This option should be explored prior to surgical removal of the impacted canine. Indications for autotransplantation are:

- a) The canine is severely malpositioned and cannot be aligned orthodontically,
- b) There is a favorable donor tooth available i.e. a premolar or canine (surgical repositioning),
- c) There is sufficient space and bucco-palatal bone of the recipient site,
- d) The surgical procedure is expected to be minimally traumatic.

Prognosis of autotransplantation is good if:

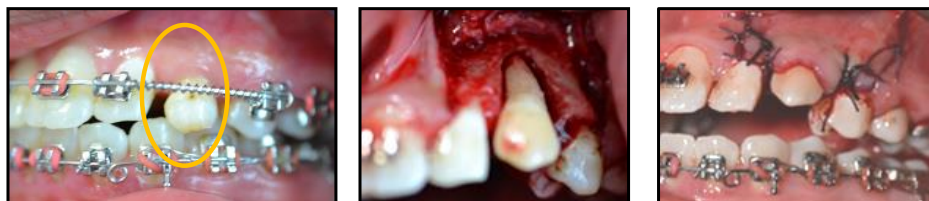- a) Patient is healthy, compliant and able to maintain a good oral hygiene.^{47, level II-2; 48-49, level III}
- b) The ideal stage of the donor tooth is when the root has $\frac{3}{4}$'s formed,^{50-51, level II-2} and an it has an open apex of more than 1 mm.^{50, 52, 54, level II-2; 53, level III}
- c) The ideal receptor alveolus has sufficient height and width to accommodate the donor tooth.^{55, level II-2; 56, level III}
- d) Surgical technique is meticulous and atraumatic,^{52, 55, 57, level II-2; 48-49, 53, level III} with reduced extra-alveolar time.^{47, 50, 55, level II-2} This is to preserve the periodontal ligament and maintain the Hertwig's Epithelial Root Sheath so that root development is not compromised. Ankylosis, root resorption and loss of epithelial adherence may also be avoided.

The patient regains a proprioceptive feeling in the transplanted teeth, with normal periodontal healing, allowing a natural feel during chewing.^{47, 57-58, level II-2; 49, level III} The induction of alveolar growth allows eruption process to occur.^{47, 50, 59, level II-2} Orthodontic treatment can be implemented if required,^{50-51, 57, 60, level II-2; 48, 53, level III} as opposed to other prosthetic replacement such as an osseointegrated implant. Orthodontic tooth movement can be started from 3-9 months after periodontal ligament (PDL) healing and before complete alveolar bone repair.^{61, level II-2} It is our concern that earlier orthodontic movement may inadvertently exert excessive forces that can reduce the success of autotransplantation.

However, the success of autotransplantation is technique sensitive and requires surgical expertise. Reports on success rate vary from 79% in a long term cohort study^{58, level II-2} to 100%^{55, level II-2} depending on the duration of follow up and criteria of success.

The most common complications of autotransplantation are ankylosis and inflammatory root resorption. However, autotransplantation may still preserve bone volume in a young patient for future implant procedure.^{48, level III}

Figure 11: Autotransplantation of impacted canine



PEC with retained deciduous canine

During procedure

After procedure

3.4 Surgical Removal of PEC

Due to prolonged treatment time with surgical exposure and alignment, surgical removal is another treatment of choice. ^{62, level II-2}

Indications:

- a) The patient refuses orthodontic treatment.
- b) When the contact between the lateral incisor and first premolar is acceptable.
- c) When pathological changes associated with the ectopic canine or radiographic evidence of early root resorption of the adjacent teeth are present.
- d) The ectopic canine is ankylosed and cannot be moved into the arch or transplanted.
- e) When the patient is willing to accept substitution of first premolar for the canine and
- f) Position of the ectopic canine is unfavourable. Prognosis for the alignment of the ectopic canine depends on its three dimensional position. ^{23, level II-3} It is unfavourable when:
 - the canine crown is tilted towards and near the midline of the arch,
 - the position of the crown tip is less than one third of the incisor roots,
 - the inclination of the canine is more horizontal,
 - canine root apex is far away from its normal position.

Clinical experience would indicate that there is a large variation in the life expectancy of retained deciduous canines. If necessary, fixed orthodontic appliances can be used to bring the first premolar forward to simulate a canine tooth or open space for a prosthetic replacement to ensure optimum aesthetic and function.

Parents and patients should be informed of the possible risks and complications associated with surgical removal of the impacted canine. A common concern is possible damage to the root of adjacent teeth.

3.5 No Intervention and Observation

Indications:

- a) The patient is not keen to undergo treatment.
- b) There should be no evidence of root resorption of adjacent teeth or other pathology.
- c) Occlusion is acceptable with satisfactory alignment of the lateral incisor and first premolar (**Figure 12**).
- d) The retained deciduous canine has an acceptable appearance and good prognosis.
- e) Severely displaced palatally ectopic canines with no evidence of pathology may be left in-situ, if the canine is remote from the dentition.

The clinician must ensure that the parents and patients understand that the prognosis of the retained deciduous canine, if present, remains unknown and a prosthesis would be required if the deciduous canine is eventually lost.

Radiographic evaluation of the ectopic canine which is left in situ is recommended to monitor for pathological changes.^{63, level III} Currently, no guideline exists as to how frequent radiographic checks should be carried out.^{20, level III} In view of radiation safety and cost considerations, annual radiographic follow-up is recommended if clinically indicated.

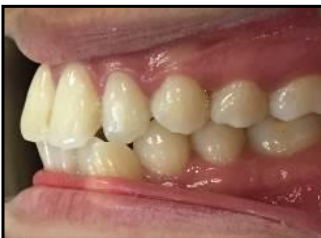

Figure 12: No intervention and observation

Occlusion is acceptable with satisfactory alignment and good contact between the lateral incisor and first premolar.

Recommendation 4

Annual radiographic follow up for PEC that is left in-situ is recommended to monitor pathological changes if clinically indicated.

(Grade C - Development Group's Recommendation)

4. CONCLUSIONS

Accurate diagnosis is important to ensure appropriate management of PEC. There are several treatment modalities available with specific indications. Factors such as patient's age, motivation and cost may affect the definitive treatment plan. Parents and patient should be informed of the various treatment options available based on existing circumstances and possible outcomes of complications.

Early monitoring of canine eruption by inspection and palpation from the age of 8 years is very important. If canine ectopia is suspected, the simple method of extracting the deciduous canine may be initiated as an interceptive procedure in suitable cases.^{2, level II-3} Inappropriate extraction of deciduous canine should be avoided to maintain the arch perimeter and prevent unnecessary trauma to the patient.

Adhering to the algorithm proposed will ensure a systematic management of the patient and timely referral to the specialist for optimal outcome.

5. IMPLEMENTING THE GUIDELINES

It is important to standardise the management of PEC at all healthcare levels in Malaysia using an evidence-based CPG in order to manage PEC appropriately. The successful treatment outcome is influenced by factors such as maintaining an up to date understanding of PEC, the use of appropriate examination techniques, treatment needs, patient records, continuing professional education and patient expectations.

5.1 Facilitating and Limiting Factors

Existing facilitating factors for these recommendations include:

- a) Wide dissemination of the CPG to healthcare professionals through printed and electronic copies.
- b) Continuing professional education on the management of PEC for healthcare professionals.
- c) Widespread of facilities at primary care level for screening and detection of PEC.

Existing barriers for application of the recommendations of the CPG include:

- a) Poor understanding or limited knowledge of PEC.
- b) Insufficient resources in the management of PEC particular at specialist care.
- c) Variation in treatment practice and preference.

5.2 Potential Resource Implications

To implement the CPG, there must be strong commitment to:

- a) Ensure widespread distribution of the CPG to healthcare professionals.
- b) Re-enforce training of healthcare professionals to ensure information is up to date.
- c) Healthcare professionals at primary care level to do screening and multidisciplinary team at secondary care level to manage the PEC.

To assist in the implementation of the CPG, the following is proposed as clinical audit indicator for quality management:

$$\text{Percentage of timely referral* of the palatally ectopic canine} = \frac{\text{No. of timely referral of the palatally ectopic canine}}{\text{Total number of referral with palatally ectopic canine}} \times 100$$

Note: *Timely referral is defined as a referral of patients between the ages of 10 to 13 years old with an unerupted and non-palpable maxillary canine (Proposed target=100%).

References

1. Peck S, Peck L & Kataja M. Site-specificity of tooth maxillary agenesis in subjects with canine malpositions. *Angle Orthod.* 1996;66:473-476.
2. Ericson S & Kuroi J. Longitudinal study and analysis of clinical supervision of maxillary canine eruption. *Community Dentistry and Oral Epidemiology.* 1986;14:172-176.
3. Hurme V. Ranges of normality in the eruption of permanent teeth. *Journal of Dentistry for Children.* 1949;16:11-15.
4. Thilander B & Jakobsson S. Local factors in impaction of maxillary canines. *Acta Odont Scand.* 1968. 26:145-168.
5. Brin I, Becker A, & Shalhav M. Position of the permanent canine in relation to anomalous or missing lateral incisors: a population study. *Eur J Orthod.* 1986.8:12-16.
6. Ericson S & Kuroi J. Radiographic examination of ectopically erupting maxillary canines. *American Journal of Orthodontics and Dentofacial Orthopedics.* 1987;91:483-92.
7. Baccetti, T. A controlled study of associated dental anomalies. *Angle Orthod.* 1998.68:267-274.
8. Chu FC, Li TK, Lui VK, Newsome PR, Chow RL, & Cheung LK. Prevalence of impacted teeth and associated pathologies - a radiographic study of the Hong Kong Chinese population. *Hong Kong Med J.* 2003.9:158-163.
9. Stivaros N & Mandall NA. Radiographic factors affecting the management of impacted upper permanent canines. *Journal of Orthodontics.* 2000 June;7(2):169-73.
10. Bishara SE. Impacted maxillary canines: a review. *American Journal of Orthodontics and Dentofacial Orthopedics.* 1992 Feb;101(2):159-71.
11. Cooke J & Wang HL. Canine Impactions: Incidence and Management. *International Journal of Periodontics & Restorative Dentistry.* 2006 Oct;26(5):483-91.
12. Peck S, Peck L & Kataja M. The palatally displaced canine as a dental anomaly of genetic origin. *The Angle Orthodontist.* 1994;64(4):249-256.
13. Camilleri S, Lewis CM, & McDonald F. Ectopic Maxillary Canines: Segregation Analysis and a Twin Study. *J Dent Res.* 2008.87(6):580-583.
14. Rimes RJ, Mitchell CNT, & Willmot DR. Maxillary incisor root resorption in relation to the ectopic canine: a review of 26 patients. *Eur J Orthod.* 1997.19:79-84.
15. Ericson S & Kuroi J. Resorption of incisors after ectopic eruption of maxillary canines: A CT study. *Angle Orthodontist.* 2000;70:415-423.
16. Ericson S, Bjerklin K, & Falahat B. Does the canine dental follicle cause resorption of permanent incisor roots? A computed tomographic study of erupting maxillary canines. *Angle Orthod.* 2002. 72:95-104.
17. McSherry PF. The ectopic maxillary canine: a review. *Br J Orthod.* 1998.25:209-216.
18. Walker L, Enciso R & Mah J. Three-dimensional localization of maxillary canines with cone beam computed tomography. *American Journal of Orthodontics and Dentofacial Orthopedics.* 2005;128: 418-423.
19. Ericson S & Kuroi J. Early treatment of palatally erupting maxillary canines by extraction of the primary canines. *European Journal of Orthodontics.* 1988;10:283-295.
20. Husain J, Burden D, McSherry P, Morris D & Allen M. National clinical guidelines for management of the palatally ectopic maxillary canine. *British Dental Journal.* 2012;213(4):25.
21. Richardson G & Russel KA. A review of impaction permanent maxillary cuspids. Diagnosis and prevention. *Journal of Canadian Dental Association.* 2000;68(9):497-501.

22. Jacobs SG. Localization of the unerupted maxillary canine: how to and when to. *American Journal of Orthodontics and Dentofacial Orthopedics*. 1999;115:314–322.
23. Southall PJ, Gravely JF. Vertical parallax radiology to localize an object in the anterior part of the maxilla. *British Journal of Orthodontics*. 1989;16:79–83.
24. Armstrong C, Johnston C, Burden D, Stevenson M. Localizing ectopic maxillary canines – horizontal or vertical parallax? *European Journal of Orthodontics*. 2003;25:585–589.
25. Counihan K, Al-Awadhi EA & Butler J. Guidelines for the assessment of the impacted maxillary canine. *Dent Update*. 2013;40:770–777.
26. Algerban A, Jacobs R, Fieuws S & Willems G. Comparison of two cone beam computed tomographic systems versus panoramic imaging for localization of impacted maxillary canines and detection of root resorption. *European Journal of Orthodontics*. 2011;33:93-102.
27. Naoumova J, Kjellberg H & Palm R. Cone-beam computed tomography for assessment of palatal displaced canine position. A methodological study. *Angle Orthodontist*. 2014b;84(3):459-466.
28. Isaacson KG, Thom AR, Horner K & Whaites E. Orthodontic Radiographs Guidelines. 3rd ed. London: British Orthodontic Society. 2008.
29. Algerban A, Jacobs R, van Keirsbilck PJ, Aly M, Swinnen S, Fieuws S & Willems G. The effect of using CBCT in the diagnosis of canine impaction and its impact on the orthodontic treatment outcome. *J Orthod Sci*. 2014 Apr;3(2):34-40.
30. Botticelli S, Verna C, Cattaneo PM, Heidmann J & Melsen B. Two- versus three-dimensional imaging in subjects with unerupted maxillary canines. *Eur J Orthod*. 2011 Aug;33(4):344-9.
31. Power SM & Short MB. An investigation into the response of palatally displaced canines to the removal of deciduous canines and assessment of factors contributing to favourable eruption. *British Journal of Orthodontic*. 1993;20:215-223.
32. Naoumova J, Kuroi J & Kjellberg H. Extraction of the deciduous canine as an interceptive treatment in children with palatally displaced canine. Part I: Shall we extract the deciduous canine or not? *European Journal of Orthodontics*. 2014a;10:1093.
33. Bazargani F, Magnuson A & Lennartsson B. Effect of interceptive extraction of deciduous canine on palatally displaced maxillary canine. *Angle Orthodontist*. 2014;84: 3-10.
34. Naoumova J, Kuroi J & Kjellberg H. Extraction of the deciduous canine as an interceptive treatment in children with palatally displaced canine. Part II: possible predictors of success and cut-off points for a spontaneous eruption. *European Journal of Orthodontics*. 2015 Apr;37(2):219-29.
35. Kokich VG & Mathews DP. Surgical and Orthodontic Management of Impacted teeth. *Dental Clinics of North America*. 1993;37:181-204.
36. Sigler LM, Bacetti T & McNamara JA. Effect of rapid maxillary expansion and transpalatal arch treatment associated with deciduous canine extraction on the eruption of palatally displaced canine: A 2-center prospective study. *American Journal of Orthodontics and Dentofacial Orthopedics*. 2011;139:E235-E244.
37. O' Neill J. Limited evidence for interceptive extraction of deciduous teeth to prevent permanent canine impaction. *Evidence Based Dentistry*. 2013;14: 23-24.
38. Parkin N, Furness S, Shah A, Thind B, Marshman Z, Glenroy G, Dyer F & Benson PE. Extraction of primary (baby) teeth for unerupted palatally displaced permanent canine teeth in children. *Cochrane Database of Systematic Reviews* 2012, Issue 12. Art. No.: CD004621. DOI: 10.1002/14651858.CD004621.pub3.
39. McSherry PF. The assessment of and treatment options for the buried maxillary canine. *Dental Update*. 1996;23(1):7-10.
40. Fleming PS, Scott P, Heidari N & DiBiase AT. Influence of Radiographic Position of Ectopic Canines on the Duration of Orthodontic Treatment. *Angle Orthodontics*. 2009 May;79(3):442–446.

41. Galloway I, Stirrup. The effect of age at the diagnosis on the complexity and treatment of palatally impacted canine. *British Journal of Orthodontics*. 1989;16:87-92.
42. Becker A & Chaushu S. Success rate and duration of orthodontic treatment for adult patients with palatally impacted maxillary canines. *American Journal of Orthodontics and Dentofacial Orthopedics*, 2003 November; 124(5):509–514.
43. Becker A, Chaushu G & Chaushu S. Analysis of failure in the treatment of impacted maxillary canines. *American Journal of Orthodontics and Dentofacial Orthopedics*. 2010 June;137(6):743-754.
44. Smailiene D, Kavaliauskiene A, Pacauskiene I, Zasciurinskiene E & Bjerklin K. Palatally impacted maxillary canines: choice of surgical-orthodontic treatment method does not influence post-treatment periodontal status. A controlled prospective study. *European Journal of Orthodontics*. 2013. doi:10.1093/ejo/cjs102. Pg1-8.
45. Parkin N, Benson PE, Thind B, Shah A. Open versus closed surgical exposure of canine teeth that are displaced in the roof of the mouth. *Cochrane Database of Syst Rev*. 2008; 4: CD006966.
46. Fischer TJ. Orthodontic Treatment Acceleration with Corticotomy-assisted Exposure of Palatally Impacted Canines. *Angle Orthodontist*. 2007; 77(3): 417-420.
47. Kim E, Jung J-Y, Cha I-H, Kum K-Y & Lee Y-S. Evaluation of the Prognosis and Causes of Failure in 182 Cases of Autogenous Tooth Transplantation. *Oral Surg Oral Med Oral Pathol Oral Radiol Endod* 2005;100:112-9.
48. Thomas S, Turner SR & Sandy JR. Autotransplantation of Teeth: Is There a Role. *British Journal of Orthodontics*. 1998;25:275-282.
49. Aslan BI, Ucuncu N, Dogan A. Long Term Follow-up of a Patient with Multiple Congenitally missing Teeth Treated with Autotransplantation and Orthodontics. *Angle Orthodontist*. 2010;80(2):396-404.
50. Tsukiboshi M. Autotransplantation of Teeth: Requirements for predictable success. *Dental Traumatology*. 2002;18:157-180.
51. Jonsson T & Sigurdsson TJ. Autotransplantation of Premolars to Premolar Sites. A Long term Follow-up Study of 40 Consecutive Patients. *American Journal of Orthodontics and Dentofacial Orthopedics*, 2004 June;125(6):668-75.
52. Andreasen JO, Paulsen HU, Yu Z, Bayer T & Schwartz O. A long-term study of 370 autotransplanted premolars. Part II. Tooth survival and pulp healing subsequent to transplantation. *European Journal of Orthodontics*. 1990 Feb;12(1):14-24.
53. Mendes RA & Rocha G. Mandibular Third Molar Autotransplantation-Literature Review with Clinical Cases. *Journal of Canadian Dental Association*. 2004;70(11):761-766.
54. Marques-Ferreira M, Rabaca-Botelho M-F, Carvalho L, Oliveiros B & Palmeirao-Carrilho E-V. Autogenous Tooth Autotransplantation: Evaluation of Pulp Tissue Regeneration. *Med Oral Patol Oral Cir Bucal*. 2011 Nov;16(7):e984-e989.
55. Kvint S, Lindsten R, Magnusson A, Nilsson P & Bjerklin K. Autotransplantation of Teeth in 215 patients – A follow up study. *Angle Othodontists*. 2010;80(3):446-451.
56. Northway W. Autogenic Dental Transplant. *American Journal of Orthodontics and Dentofacial Orthopedics*. 2002;121(6):592-593.
57. Diaz JA & Zoror CE. Long-term Evaluation and Clinical Outcomes of Children with Dental Transplants in Temuco City, Chile. *Eur J Paediatr Dent*. 2014 Mar;15(1):6-12.
58. Czochrowska EM, Stenvik A, Bjercke B & Zachrisson BU. Outcome of Tooth Transplantation: Survival and Success Rates 17-41 Years Post Treatment. *American Journal of Orthodontics and Dentofacial Orthopedics*. 2002;121:110-119.
59. Paulsen HU, Andreasen JO. Eruption of Premolars Subsequent to Autotransplantation. A longitudinal radiographic study. *European Journal of Orthodontics*. 1998;20:45-55.

60. Andreasen JO, Paulsen HU, Yu Z & Schwartz O. A long-term study of 370 autotransplanted premolars. Part III. Periodontal healing subsequent to transplantation. *European Journal of Orthodontics*. 1990 Feb; 12(1):25-37.
61. Paulsen HU, Andreasen JO, Schwartz O. Pulp and periodontal healing, root development and root resorption subsequent to transplantation and orthodontic rotation: A long-term study of autotransplanted premolars. *American Journal of Orthodontics and Dentofacial Orthopedics*. 1995;108(6): 630-640.
62. Sagne S & Thilander B. Transalveolar transplantation of maxillary canine: A follow up study. *European Journal of Orthodontics*. 1990;12:140-147.
63. Houston WJB & Tulley WJ. *A Textbook of Orthodontics*. 1998: p187. Bristol Wright 2002.

Glossary

1. Irradiation

- Exposure or subjection to the action of radiation for diagnostic or therapeutic purposes.

2. Ankylosis

- The periodontal ligament is obliterated in one or more localized areas, and a bony bridge is formed by penetration of alveolar bone into the cementum.

3. Dilaceration

- A developmental distortion of the form of a tooth, whereby the root or the apex forms an angle with the long axis of the tooth (the tooth appears sharply curved or bent).

4. Iatrogenic

- An unfavorable response or condition caused by medical or dental personnel, diagnostic tests or treatment procedures.

5. Idiopathic

- Pain, disease or disorder of unknown etiology.

6. CBCT

- Cone Beam Computed Tomography (CBCT) is a diagnostic imaging modality that provides high-quality, accurate three-dimensional (3D) representations of the osseous elements of the maxillofacial skeleton.

7. CT

- Computerised Tomography (CT) is an imaging method that employs a narrowly collimated radiographic beam that passes through the body and is recorded by an array of scintillation detectors.

8. Root resorption

- A loss of substance from the root tissues that normally are mineralized such as dentin or cementum.

9. Extra-alveolar

- Alveolar - the bone making up the alveolar process of the jaws.
- Extra- alveolar - located outside the bone making up the alveolar process of the jaws.

10. Hertwig's Epithelial Root Sheath

- Hertwig's epithelial root sheath is an elongation of the cervical loop, which helps determine the shape, size, and number of roots and which influences the formation of dentin in the root area during the developmental stages of a tooth.

11. Ectopic

- Located away from the normal position.

12. DPT

- Dental panoramic tomography (DPT) is a radiographic tomogram of the jaws, taken with a specialized machine designed to present a panoramic view of the full circumferential length of the jaws on a single film.

13. Orthodontics

- The branch of dentistry concerned with facial growth with development of the dentition and occlusion, and with the diagnosis, interception and treatment occlusal anomalies.

14. Autotransplantation

- The transfer of teeth from one site to another in the same individual, into extraction sites or surgically prepared sockets.

15. Deciduous dentition

- Primary teeth (baby teeth).

16. Neoplastic

- Relating to, or constituting a tumor or neoplasia.

17. Interceptive Orthodontics

- Any treatment which eliminates or reduces the severity of a developing malocclusion in order to eliminate or simplify the need for future treatment.

18. Cystic

- An abnormal membranous sac in the body containing a gaseous, liquid, or semisolid substance.

19. Parallax technique

- The apparent displacement of an object that follows a change in the position from which it is viewed.

20. Periapical

- Surrounding the apex of the root of a tooth.

21. In-situ

- In its normal place; confined to the site of origin.

22. Prevalence

- The number of people in a population who have a disease at a given time, the numerator is the number of existing cases of disease at a specified time and the denominator is the total population. Time may be a point or a defined interval, and is traditionally the former if unspecified.

23. Aetiology

- Cause of disease.

24. Palatal

- Relating to the roof of the mouth.

25. Buccal

- In the direction of the cheeks.

26. Referred pain

- Pain perceived in an area distant to and unrelated to the true site of origin.

27. Randomised controlled trial

- A trial in which participants are assigned by chance to receive either an experimental or control treatment. When randomisation is done properly, the effect of a treatment(s) can be studied in groups of people who are:
 - i. The same at the outset, and
 - ii. Treated the same way, except for the intervention(s) being studied. Any differences seen in the groups at the end can be attributed to the difference in treatment alone, and not to bias or chance.

28. Corticotomy

- A partial osteotomy, involving only the cortical plate, to weaken the resistance of the bone to the application of forces.

29. Proprioceptive

- A sense providing knowledge of the position of those parts and regions of the body.

30. Osseointegrate

- A direct structural connection between bone and the surface of a structure.

31. Cohort study

- In research and statistics, a group of individuals who share a characteristic at some specific time and who are then followed forward in time, with data being collected at one or more suitable intervals.

32. Retrospective study

- A study which is conducted looking backward, or directed toward the past.

33. Surgical exposure

- Surgical uncovering of an unerupted or impacted tooth.

34. Prosthesis

- A device that replaces missing body parts.

35. Pathology

- The form of medical science and specialty practice concerned with all aspects of disease, but with special reference to the essential nature, causes, and development of abnormal conditions, as well as the structural and functional changes that result from the disease processes.

36. Orthodontic Specialist

- A graduate of an accredited dental school who additionally has followed a postgraduate full time academic program in orthodontics, in accordance with the requirements of his/her national state, or provincial law.

37. Algorithm

- A step-by-step method of solving a problem or making decisions, as in making a diagnosis.

38. Clinically missing teeth

- The absence of teeth from the dentition because of congenital factors, exfoliation or extraction.

LIST OF ABBREVIATIONS

CBCT	Cone-Beam Computed Tomography
CPG	Clinical Practice Guidelines
CT	Computed Tomography
DPT	Dental Panoramic Tomogram
HTA	Health Technology Assessment
MOH	Ministry of Health
OHD	Oral Health Division
PEC	Palatally Ectopic Canine
PDL	Periodontal Ligament
RCT	Randomised Controlled Trial
SIGN	Scottish Intercollegiate Guidelines Network
USPSTF	United States Preventive Services Task Force

ACKNOWLEDGEMENTS

The members of the development group of these guidelines express their gratitude and appreciation to the following for their contributions:

- Panel of internal and external reviewers
- Technical Advisory Committee for CPG for their valuable input and feedback
- Dr Noor Hasmin bt. Mokhtar and Ms Zabidah bt. Othman for processes involved in the publication
- Patients who have consented for the archiving of their clinical photos
- All others who have contributed directly or indirectly to the development of the CPG

DISCLOSURE STATEMENT

The panel members had completed disclosure forms. None held shares in pharmaceutical firms or act as consultants to such firms. Details are available upon request from the CPG Secretariat.

SOURCE OF FUNDING

The development of the CPG on “**Management of the Palatally Ectopic Canine**” was wholly supported financially by the Ministry of Health Malaysia and was developed without any involvement of the pharmaceutical industry.

Notes



Oral Health Technology Section
Oral Health Division
Ministry of Health Malaysia
Level 5, Block E10, Precinct 1
Federal Government Offices Centre
62590 Putrajaya, Malaysia

ISBN 9789670769561



9 789670 769561